

# Annular subvalvular left ventricular aneurysm: a case report

\*JG HAKIM, \*IT GANGAIDZO, \*\*D CHIMUKA

Annular subvalvular left ventricular aneurysm is a curious condition that has predominantly been seen in Africans. We describe a 36 year old man who presented with chest pain, recurrent syncope and left ventricular failure, and was found to have a typically located annular subvalvular left ventricular aneurysm. The aneurysm initially perforated into the left atrium and terminally ruptured along its free wall. The lesion was fully defined by colour doppler echocardiography and later confirmed at autopsy. Such aneurysms are not uncommon in Africa and need to be considered in the differential diagnosis of cardiac presentations, as appropriate and timely treatment can be effective.

## Introduction

Annular subvalvular left ventricular aneurysm is a rare condition that has been described predominantly in southern and western African Black patients.<sup>1</sup> Sporadic cases have, however, been reported among Blacks in several parts of Africa and indeed among a few Caucasians worldwide.<sup>2</sup> A report in 1979 described the case of a Zimbabwean living in South Africa who died of complications related to this condition.<sup>3</sup> Although the features of annular subvalvular left ventricular aneurysm were recognized as early as 1813, it was Abrahams working in Nigeria in 1962 who described a series of 12 patients identifying this condition as a distinct clinicopathological entity. In this article we report a patient with annular subvalvular aneurysm which perforated initially into the left atrium and later along the free wall causing sudden death of the patient.

## Case Report

A 36 year old male African presented with a two months history of episodic, non-effort related, burning retrosternal chest pain worsened by lying on the right decubitus position. There was a further history of dyspnoea on exertion,

orthopnoea and a non-productive cough. He denied a past history of rheumatic fever, hypertension or other major risk factors of coronary artery disease such as hyperlipidaemia, smoking, diabetes or a family history of premature coronary artery disease or sudden death.

He had a temperature of 37.6°C with shotty cervical and epitrochlear lymphadenopathy. There was no pedal oedema. His pulse was of normal volume and regular at 82/minute and the blood pressure 140/60 mmHg. The jugular venous pressure was not elevated. The apex beat was not displaced and on cardiac auscultation there were no gallops or murmurs. The lung bases were clear and the liver was not enlarged. The rest of the abdominal and neurological examination was normal.

The haemoglobin was 10.0 g/dl, the platelet count  $502 \times 10^9/L$  and the total white cell count  $8.4 \times 10^9/L$  with a normal differential count. The erythrocyte sedimentation rate was (ESR) 131 mm in the first hour. The cardiac enzymes were normal with creatine kinase 151 U/L (normal range 0 to 229), hydroxybutyrate dehydrogenase 189 U/L (normal range 70 to 190) and aspartate aminotransferase 20 U/L (normal range 21 to 40). The 12-lead electrocardiogram showed a normal regular sinus rhythm of 86/minute, a normal QRS axis of +75°, with no pathological Q-waves or signs of ventricular hypertrophy. The T-waves were reduced in amplitude or flat

\*Department of Medicine and Clinical Epidemiology Unit  
University of Zimbabwe Medical School

P O Box A 178, Avondale, Harare, Zimbabwe

\*\*Division of Surgery and Clinical Epidemiology Unit

Parirenyatwa Hospital

P O Box CY 198, Causeway

Harare, Zimbabwe

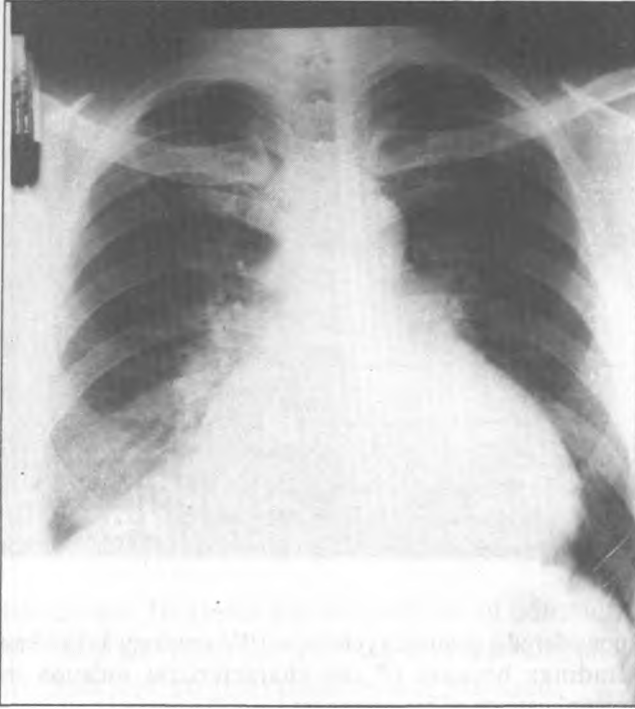
Correspondence and reprint requests to:

Dr J Hakim

Tel:791631, E-mail:ceuj@healthnet.zw

in leads I, aVL, V5 and V6. No ST-segment elevation or depression was observed in any lead. The chest X-ray showed cardiomegaly with a cardiothoracic ratio of 76%, a diffuse bulge of the left cardiac border, hilar congestion and upper lobe blood diversion (Figure I).

*Figure I: Chest radiograph showing cardiomegaly mainly due to a large annular subvalvular left ventricular aneurysm causing a distinct bulge of the left cardiac border. There is evidence of pulmonary venous congestion.*



Colour doppler echocardiography demonstrated a unilocular subvalvular left ventricular aneurysm measuring 7 x 6 cm located just beneath the mitral valve annulus and communicating via a single ostium with the left ventricular cavity (Figures II and III).

There was a superior communication with the left atrium with the site of rupture clearly demonstrated by colour flow imaging. Overall left ventricular function appeared impaired with systolic expansion of the aneurysm. All cardiac valves and the pericardium were normal. On account of his constitutional symptoms, anaemia and elevated ESR human immunodeficiency syndrome infection was considered, but consent for the test was declined. Tuberculous pericarditis was initially considered because of the cardiomegaly, but when the true nature of his condition became evident he was put on diuretics for left ventricular failure.

On regular review over the course of the next six months he reported several attacks of palpitations of sudden onset and offset. He also experienced frequent episodes of near-syncope and three of actual syncope. The fever resolved and his symptoms of heart failure were controlled and cardiovascular examination during follow up remained unremarkable. During the course of his management he was advised to have a 24-Holter monitor examination for detection of arrhythmias and to undergo surgical excision of the aneurysm. He was undecided over the whole period of consultation and whilst still vacillating he suddenly collapsed and died.

*Figure II: Parasternal long-axis echocardiographic view showing a large annular subvalvular left ventricle aneurysm communicating with both the left ventricular to the posterior mitral valve leaflet and with the left atrium. RV-right ventricle, LV-left ventricle, Ao-aorta, MV-mitral valve.*

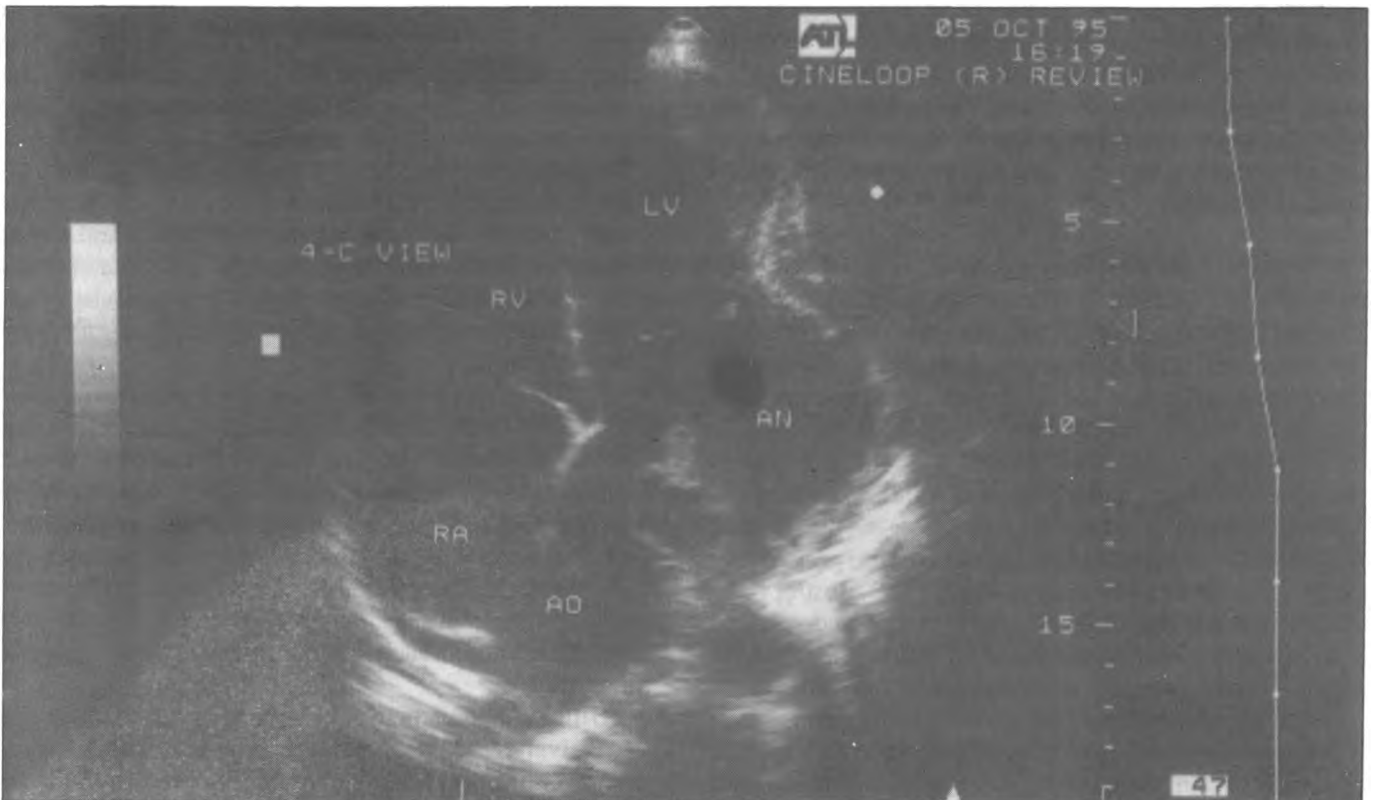
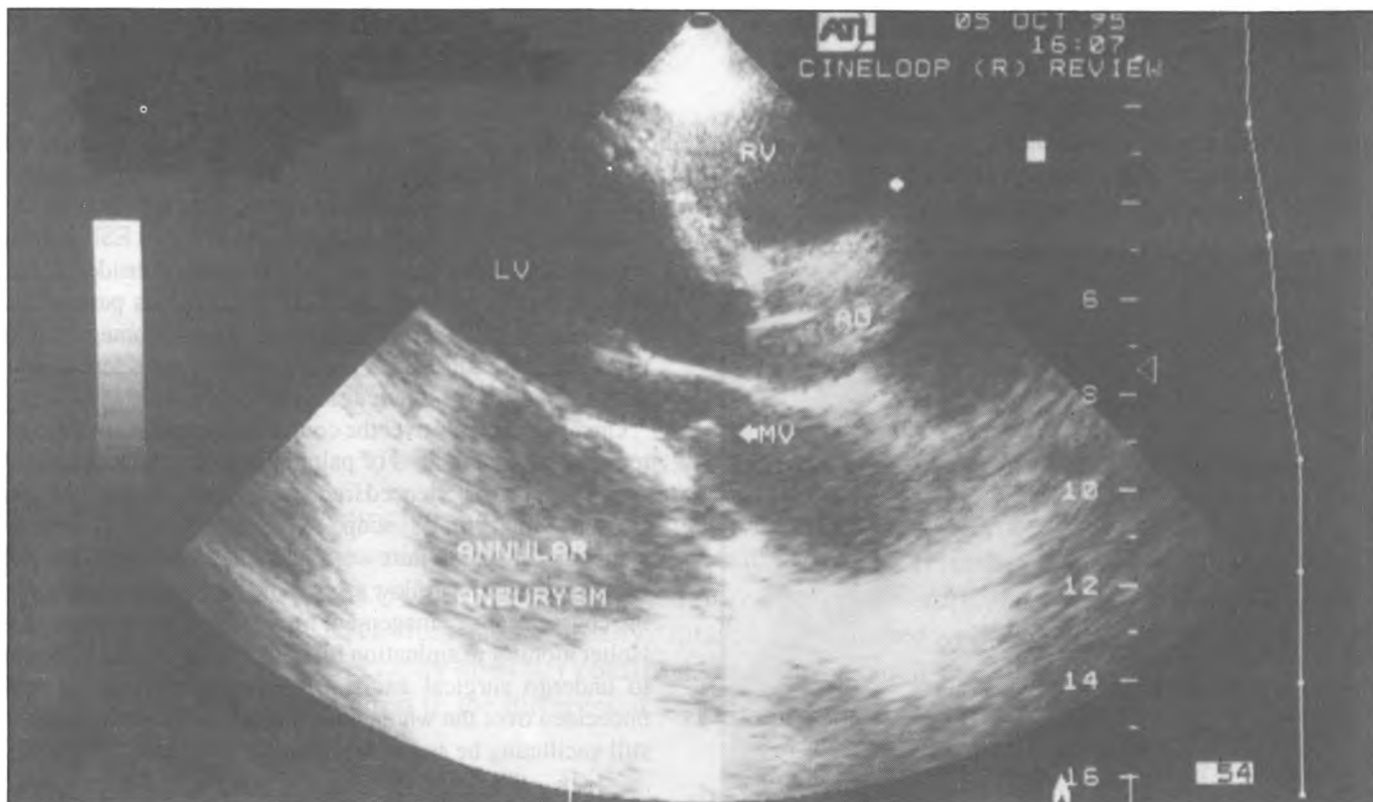
Figure III: Four chamber echocardiographic view showing an annular subvalvular left ventricular aneurysm (AN) seen as a large bulge on the lateral surface of the left ventricle (LV). Communications with the left ventricular cavity and the rather squashed left atrium are evident. RV-right ventricle, RA-right atrium, Ao-aorta. Note: the left atrium is not labelled.



At autopsy an annular subvalvular aneurysm was found involving the posterior ventricular wall just below the atrio-ventricular junction. It extended superiorly between the pulmonary veins stretching them. There was a communication with the posterior left atrial wall. The ventricular opening of the aneurysm was partially covered by the posterior mitral valve leaflet. The wall of the aneurysm was paper thin and its cavity was lined by laminar clots. The pericardium was not adherent to the aneurysm, hence the free-wall rupture was into the pericardial sac which resulted in the terminal and fatal acute tamponade.

### Discussion

The commonest cause of left ventricular aneurysms is atherosclerotic coronary artery disease complicated by myocardial infarction and aneurysm development. Even though the incidence of coronary artery disease appears to be rising among Zimbabwean Blacks<sup>4</sup> it is still a relatively infrequent condition, and left ventricular aneurysms from this cause have not assumed a high prominence. The other causes of left ventricular aneurysms include trauma, post cardiac surgery, bacterial endocarditis and syphilis.<sup>5</sup> Most of these causes are sufficiently rare to be considered medical curiosities.<sup>1</sup> Syphilis serology and HIV testing would have completed our patient's aneurysm work up. Nonetheless, annular subvalvular aneurysms are sufficiently distinctive on echocardiographic and pathological evaluation for a specific diagnosis to be made.<sup>3</sup> In fact, in our patient we would have

considered a positive syphilis or HIV serology as incidental findings because of the characteristic location and complications of his aneurysm.

Annular subvalvular aneurysms arise immediately beneath the mitral and aortic valves apparently due to an inherent weakness of the left ventricular wall in the region of the atrioventricular groove. Why this weakness occurs predominantly in the Black race and whether there are other predisposing environmental or dietary factors is not known. The aneurysms may be unilocular or multiloculated with single or multiple ostia opening into the left ventricular cavity. Aneurysms can arise in relation to the mitral or aortic valves or in both locations. They can grow in a variety of directions, extending inward into the interventricular septum, upward into the left atrium or outward onto the free border of the left ventricle.<sup>1</sup>

Annular subvalvular left ventricular aneurysms have been seen in both males and females and may present from the first decade to middle age. The clinical features are variable; patients may be entirely asymptomatic or may present with cardiac failure, embolism, angina or sudden death from cardiac rupture or arrhythmias. Mitral regurgitation is a frequent finding, but we did not detect this either clinically or echocardiographically in our patient. Rupture of the aneurysm into the left atrium such as in our patient has previously been described.<sup>2,6</sup>

Hitherto, confirmation of the diagnosis of annular subvalvular aneurysm has been by ventriculography or autopsy. However, with the advent of doppler

echocardiography an accurate morphological definition of the aneurysm, its extent and complications can be made non-invasively and *antemortem*. Electrocardiography and especially Holter monitoring is useful in this condition to detect arrhythmias which may be episodic.<sup>3</sup> Because the aneurysm can impinge on the left coronary artery especially the left circumflex branch, coronary angiography has a place in further elucidating symptoms and may be essential before surgery to localize the coronary vessel in relation to the aneurysm.

Supportive medical treatment is essential for cardiac failure, angina, arrhythmias and embolism. However, the definitive treatment of annular subvalvular aneurysms is surgical excision with valve repair or replacement for any associated incompetence.<sup>2</sup>

In conclusion, we would like to add to the literature our own Zimbabwean experience of this rare and fascinating condition. The lesion was fully defined *antemortem* by doppler echocardiography and the findings later confirmed at autopsy.

## References

1. Abrahams DG, Barton CJ, Cockshott WP, Edington GM, Weaver EJM. Annular subvalvular left ventricular aneurysms. *Q J Med* 1962;31:345-60.
2. Antunes M de J. Submitral left ventricular aneurysms: correction by a new transatrial approach. *Thor Cardiovasc Surg* 1987;94:241-5.
3. Wolpowitz A, Arman B, Barnard MS, Barnard CN. Annular subvalvular idiopathic left ventricular aneurysms in the Black African. *Ann Thorac Med* 1979;27:351-5.
4. Hakim JG, Odwee MG, Siziya S, Ternouth I, Matenga JA. Acute myocardial infarction in Zimbabwe: the changing scene of coronary artery disease. *Cent Afr J Med* 1995;41:303-8.
5. Lurie AO. Left ventricular aneurysm in the African. *Br Heart J* 1960;22:181-8.
6. Chesler E, Joffe N, Schamroth L, Meyers A. Annular subvalvular left ventricular aneurysms in the South African Bantu. *Circ* 1965;32:43-51.

Faculty of Medicine,  
Department of Anatomy  
University of Zimbabwe  
P O Box MP 167, Mount Pleasant  
Harare, Zimbabwe

Correspondence to:  
Dr SA Asala