

## Sickle Cell Anaemia in an African Infant from Northern Rhodesia

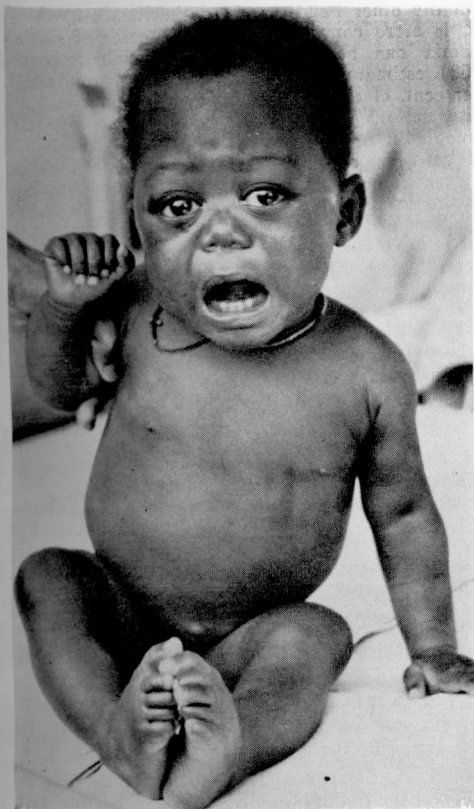BY

MICHAEL GELFAND, C.B.E., M.D., F.R.C.P.  
*Physician, Harari Hospital.*

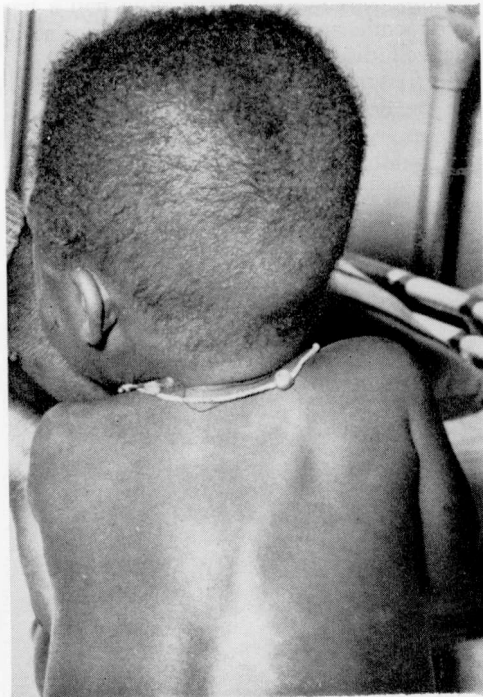
Adesi was a female baby aged about 10 months whose parents had come down from Fort Jameson, in Northern Rhodesia, to work in Salisbury, Southern Rhodesia. Both parents were indigenous to Northern Rhodesia, the father being an Achewa and the mother an Angoni.

On 12th May, 1958, the baby was admitted to the Harari African hospital with only one day's history of illness of cough, vomiting and diarrhoea, although from her sickly appearance she must have been ill much longer. The child looked ill and thin and was extremely pale. Both her eyes were proptosed (since birth) (Fig. 1), but there was no jaundice or fever. The spleen was enlarged to two fingers below the left costal margin and was firm, but the liver was not palpable.

A very striking feature on examination was the bossing of the child's head (Fig. 2), but



Prominence of the eyes, more so on the right side.



The bossing of the skull is clearly shown.

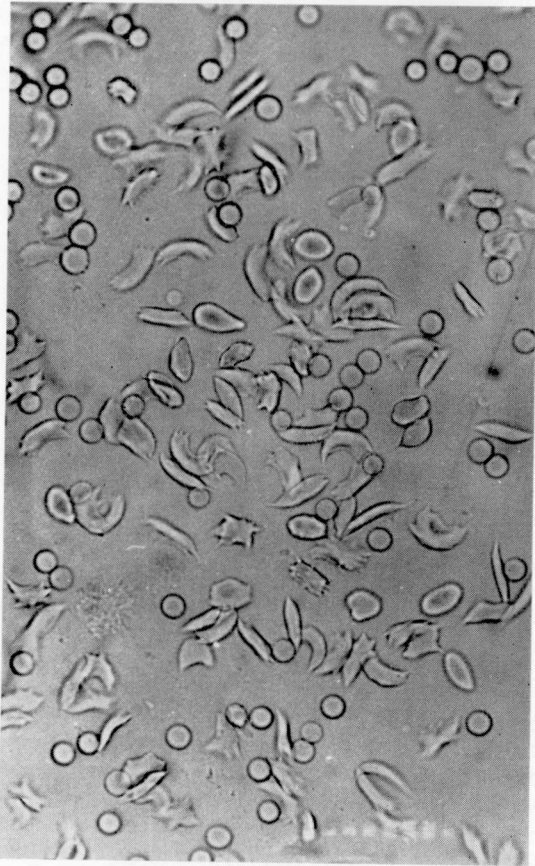
sickle cell anaemia was not considered at the time. As the duration of the illness obtained from the mother was so short and the anaemia so intense, we decided to treat her for malaria, although no parasites were found in the blood. Nivoquin and quinine were given intramuscularly as well as Imferon and Vi-Daylin.

The haemoglobin was 25 per cent. and red cells one million per cm. (haemoglobin 3.7 g. per cent.); P.C.V., 20 per cent.; M.C.V., 180 mcu., and M.C.H.V. 18 per cent. The total white cell count was 18,000 (neut. 84 per cent., lymphocytes 13 per cent., monocytes 1 per cent. and eosinophils were 2 per cent.). The blood film showed marked signs of marrow regeneration. On 20th May, 1958, a transfusion of 300 c.c. of whole blood was administered. On 9th June the reticulocyte count was 5 per cent., and on 30th June it had risen to 13 per cent. On 22nd May the haemoglobin had risen to 70 per cent. haem. (10.3 g. per cent.), but on 28th May it had fallen to 63 per cent. (19.2 g. per cent.), the red cell count being 2.54 million per c.mm.

Owing to the peculiar shape of the infant's head an X-ray was taken of its skull, and in the lateral view a definite hair-on-end appearance was evident in the frontal region. We

were now convinced that the child had a haemolytic anaemia and so began to consider seriously sickle cell disease.

The first report issued stated that no sickling could be demonstrated, but when this examination was repeated, sickle cells were found in large numbers (Fig. 3). By electrophoresis,



The extent of sickling in the infant's blood.

both A and S blood was shown to be present on the filter paper, and the presence of the A was attributed to the transfusion the child received before and to the fact that when the test was repeated on subsequent occasions, the amount of A haemoglobin became progressively less. Hendrickse (1958) mentions that transfused cells may take a period from three to four months before they disappear from the blood. Although no sickling trait could be demonstrated in the father, the mother was shown to be a sickler.

Adesi next contracted measles and was sent to the Infectious Diseases Hospital, Salisbury,

where she recovered, but she did not survive long after her return to the Harari hospital, where she died in August, 1958. Permission for an autopsy was refused.

COMMENTS

I believe that the child had sickle cell anaemia because of the severe anaemia, the sickling of its red cells, and the hair-on-end appearance of the skull bones, which denoted a haemolytic anaemia. The mother showed the sickle trait.

Sickle cell anaemia is very rare in my experience in Southern Rhodesia among the Mashona, so much so that in 1955 I reported the disease in an African child of Mashona origin who was born in Mtoko. The sickling trait itself is very uncommon, and in 120 cases of Africans of pure Shona descent studied so far by the filter electrophoresis paper method, no abnormal haemoglobin could be demonstrated (Seymour and Gelfand, to be published).

Further, thalassaemia has not been recorded in Rhodesia, and haemoglobin F was not demonstrated in 60 consecutive Shona males studied by Seymour and Gelfand.

On the other hand, north of the Zambesi, where the trait is more common, many more cases of sickle cell anaemia can be expected. The Lambotte-Legrandes (1958) estimate that in many areas of tropical Africa 1 per cent. of children suffer from this anaemia—a sufficiently serious condition. They state that normal adult haemoglobin A is not found in sickle cell anaemia; but, as I have suggested, the presence of A haemoglobin in the case under review could be explained by the fact that the infant was transfused recently with blood. If the infant had only a sickle cell trait it would be difficult to explain the skull changes and the severe anaemia. The absence of an icterus should not be considered a serious criterion against a diagnosis of sickle cell anaemia, as Trowell *et al.* (1957) showed that jaundice is not constantly present and the Lambotte-Legrandes (1958) point out that jaundice is often mild in early infancy, although it may become severe during a crisis.

SUMMARY

An African infant whose parents were indigenous to Northern Rhodesia was found to have sickle cell anaemia. The clinical features of the case are given.

ACKNOWLEDGMENTS

I wish to thank Dr. W. Murray for his permission to publish this paper.

REFERENCES

GELFAND, M. (1955). *Trans. Roy. Soc. trop. Med Hyg.*, 49, 268.  
 LAMBOTTE-LEGRANDE, J. & C. (1958). *Diseases of the Tropics and Sub-Tropics*. Edward Arnold Ltd., Lond.  
 HENDRICKSE, R. G. (1958). *W. Afr. Med. J.*, 7, 2.  
 SEYMOUR, A. & GELFAND, M. (to be published).  
 TROWELL, H. C., RAPER, A. B. & WELBOURN, H. F. (1957). *Quart. J. Med.*, 26, 401.