

The Central African Journal of Medicine

Volume 18

JULY, 1972

No. 7

North American Blastomycosis in Rhodesia

BY
LINDSAY DAVIDSON
AND
MICHAEL GELFAND

Department of Medicine, University of Rhodesia.

INTRODUCTION

The clinical and pathological features of North American Blastomycosis in the United States of America have been well documented by Abernathy (1959) and by Witorsch & Utz (1968) who showed that blastomycosis is a chronic mycosis generally believed to begin in the lungs and which then spreads to other organs giving rise to secondary lesions, especially in the skin and bones.

The first suggestion of the existence of this disease in Africa came in 1952 from Tunisia where *Blastomyces dermatitidis* was isolated from lesions in skin and bone. (Vermeil *et al.*, 1954). The validity of Vermeil's case was questioned as subcultures of the organs did not sporulate. A second case was diagnosed on histological evidence in Tunisia and a third patient, originally from Tunis, was reported with the disease in Toulouse in France (Drouhet *et al.*, 1968). A fourth patient, in whom the organism was isolated and identified was reported from Casablanca (quoted by Magalhaes M. J. Campos, 1967). In 1964 Emmons, his colleague, reported one case from Uganda and another from South Africa and Gatti and his colleagues reported two patients from the Congo Kinshasa 1964 and 1968. In 1967 M. J. Campos Magalhaes reported the isolation of *Blastomyces dermatitidis* from the sputum of an 18-year-old African leper with granulomatous lesions in lung, prostate and on the skin of the right foot.

Thus by 1968 four patients with this disease had been from Africa north of the Sahara and five cases from scattered areas south of the

Dr. Lindsay Davidson, M.D., F.R.C.P., was the Professor and first head of the Department of Medicine until his departure for Cardiff where he is a Consultant Physician to the Cardiff Group of Hospitals.

Sahara apart from Rhodesia. Indications that this disease or a similar disease were much commoner than had been realised, was given by the report of Ross and Goldring in 1966 who described the pathological findings in five patients from Rhodesia with the condition. The clinical and pathological findings in all the patients correspond very closely to those described from other parts of Africa and cultural proof of the presence of *Blastomyces dermatitidis* was obtained in two patients. Since this initial report we have had experience of a further nine patients of whom eight are sufficiently well documented to be reported in detail here.

The disease is believed to be contracted by the inhalation of spores from contaminated soil and initially we thought that all cases were infected in one small area of this country but we now know that the organism must be widespread as we have seen patients from every major agricultural area with this disease.

CASE I

Smoke Shadreck—a Zambian male labourer of about 48 years living in the Sipolilo district of Rhodesia was admitted in January 1967 complaining of a swelling of both legs for two days. Direct questioning elicited symptoms of two months cough, right pleural pain and haemoptysis. He had no other symptoms or previous illnesses. On examination he was wasted and febrile but without lymphadenopathy, jaundice, clubbing, oedema or pallor. The cardiovascular system was normal with a blood pressure of 130/80 millimetres of mercury. There were no abnormal signs in the central nervous system or in the abdomen and in particular the liver and spleen were not enlarged. In the chest rhonchi were audible over the right lower lobe. The striking feature of the examination however, was the presence of fluctuant abscesses below the right scapula and below the left lateral malleolus. In addition both ankles were tender and swollen as was the right knee and there was extreme tenderness over the lower end of the left tibia. The left wrist was fixed but not tender. Examination of the blood showed a haemoglobin of 7.4 g./100 ml., a polymorphonuclear leucocytosis of

16,500 cu. mm., a high erythrocyte sedimentation rate 140 (Westergren) and a low serum albumen 1.3 gms/100 ml. Total serum proteins were 6.30G% and the serum electrolytes and urea were normal. Radiological examination showed that the clinically detectable abscesses appeared to arise from underlying osteolytic lesions in the tibia, humerus and ribs and that there was a left basal empyema.

A gram stained film from one of the abscesses showed polymorphonuclear cells and was also reported as showing scanty fungal spores. Cultures both aerobic and anaerobic showed no growth. During January further abscesses developed on the lateral malleolus of the right ankle and the medial aspect of the right knee. Unfortunately an original report of fungus spores in pus were overlooked and in spite of general supportive measures including transfusion the patient gradually deteriorated, dying on the 22nd of February.

At autopsy the significant findings were widespread consolidation in all lobes of both lungs and collections of pus in the right psoas muscle, left elbow joint, lower end of the left humerus, the left carpus and in the fourth and fifth dorsal vertebrae.

Histological examination of lung tissue showed widespread consolidation with the alveoli filled with mononuclear and giant cells. Round or oval fungi with thick walls were seen in the giant cells or free in exudate and in places were budding. The organisms were P.A.S. positive and stained strongly with hexamine silver and morphologically were characteristic of *Blastomyces dermatitidis*.

CASE II.

Aloni Ringson—originating from Malawi, aged about 32 years, was a farm labourer in Banket in an adjacent area to Case I. He was admitted in November 1967 under Mr. Allan White, because of a painless granulomatous ulcer on his nose, which had been present for six months after starting as a subcutaneous swelling. In addition his right ankle joint had become painful and swollen five months prior to admission. On examination he was a thin man with an obvious granulomatous ulcer eroding the tip of his nose but without regional lymph node enlargement. The cardiovascular stem was normal, the blood pressure being 120/80 mm. Hg. In the respiratory system coarse crepitations were audible over the right upper zone anteriorly. The abdomen was normal without the liver and spleen

being enlarged. The patient was slightly pyrexial (99-100°F). Examination of the blood showed haemoglobin 11.8g. per 100 ml., a normal leucocyte count of 4300 per cu. mm. with normal differential count, a high sedimentation rate of 116 mm. per hour (Westergren). Other investigations were negative except for the presence of viable ova of *S. mansoni* and cysts of *Iodamoeba butschlii* in the stool. X-ray of the chest revealed a rounded dense area of consolidation about 2 in. in diameter in the right upper zone. Sputum was repeatedly negative for tubercle bacilli. A histological report on a biopsy taken from the nasal ulcer said the dermis is heavily infiltrated with plasma cells, lymphocytes, giant cells and a few neutrophils. P.A.S. and hexamine silver stains showed round fungal bodies in the pus. In one section budding was suspicious. The type of fungus can only be definitely identified by culture but this could be *Blastomyces dermatitidis*.

The patient who had been placed on anti-tuberculosis therapy pending the biopsy report, was then changed on to Amphotericin B. but reacted rather severely to the treatment after only three injections with nausea and vomiting and in spite of efforts to dissuade him he took his own discharge from hospital at this point. He was re-admitted 18 months later but now his face was really affected by an ulcerating rash covering the nose, nostril and upper lip and extending well on to both cheeks with erosion of the alae nasi and upper lip and ectropion on the left. He was afebrile but looked ill and pale. There were now large lymph nodes in the left axilla and right supraclavicular fossa and the liver was two fingers enlarged. In the respiratory system scattered rhonchi were heard throughout both lung fields but the cardiovascular system remained normal. The patient's main complaints however, were related to the central nervous system where he had a spastic paraplegia with a sensory loss level and incontinence of urine. He still had *S. mansoni* and now *Taenia Sp.* in his stool but other blood investigations were non-contributory. X-ray of the spine however, showed collapse of the vertebral body of T6 and anterior subluxation of T1 on T2. Chest X-ray showed calcified healed foci in both apices of the lungs but no cavitations or gross lesion was present in the right upper zone as previously. Further biopsy of the ulcer was reported as follows: "This is North American blastomycosis; the spinal lesion is likely to have the same cause."

The patient was treated with Amphotericin B. and after about four weeks the rash on the face was much improved and the active edge of the

lesion virtually gone. After about six months he began to move his legs and regained bladder control and by the end of 1969 after a total of 1½ grams of Amphotericin he was apparently cured of the infection but had a residual spastic paraplegia although capable of walking with crutches.

CASE III

Pontamine Sekera—aged about 45 years was admitted to Harare Hospital in July, 1965. He originated from Tete in Mozambique, but he had been living on a farm at Shamva, 60 miles from cases I and II for four years. His main complaint was of a month's history of ulcers on the chest wall and in addition he complained of a cough. On examination there was no general abnormalities; examination of the cardiovascular system, respiratory system, central nervous system and abdomen were normal. The ulcers of which he complained were observed over the chest especially over the lower back. X-rays of the chest wall showed osteolytic lesions of the third and sixth right ribs and X-ray of the lumbodorsal spine revealed collapse and absorption of the twelfth thoracic vertebrae. The only other feature on examination was a marked simple colloid goitre with some tracheal displacement. Haemoglobin was 11.2 gms% white cell count was normal with normal distribution and the erythrocyte sedimentation was 119 mm. (Westergren). Curettings from one of the sinuses were submitted for histological examination as was granulation tissue from an ulcer. The report was: "This is granulation tissue in which numerous thickwalled, spherical, occasional budding organisms are present. Many are in macrophages or giant cells. The appearance is that of blastomycosis, an unexpected condition in Central Africa."

The patient was treated from September to November 1966 with Amphotericin B. and was discharged in November apparently cured after receiving approximately 1 200 mg. of the drug.

CASE IV.

Chigonro Rabbie—a female aged 23 years from the Chipuriro Tribal Trust area was admitted to hospital in April 1968 with a ten month history of pain in the back, abdomen and legs. She had been referred from a district hospital where she had been admitted two months earlier because of a sinus in her back and following radiological examination was treated with antituberculous drugs in the belief that she had tuberculous spondylitis. She had also been treated for *S. haematobium* in the district hospital. On questioning, she had had amenorrhoea since her

last child aged 3½ years and also had had some haemoptysis for about one week three months prior to admission. On examination she was very thin and afebrile with enlarged rubbery lymph nodes in the right inguinal region, but with no hepatosplenomegaly. Systemic examination of the other systems was negative. Over the region of the third and fourth lumbar vertebrae there was a marked gibbus with two sinuses discharging pus. Radiological examination showed normal lungs but destruction of the third and fourth lumbar vertebrae. (Fig. 1.) Other investigations showed a haemoglobin of 10.7C%, a normal white cell and differential count, normal serum electrolytes and urea, normal serum albumen with somewhat raised serum bilirubin Protein and casts were reported in the urine. The pus swab showed no growth anaerobically or aerobically. Antituberculous therapy was continued and a month after admission Mr. Roper operated on the patient finding a grossly diseased disc and abscess between the third and fourth lumbar vertebrae. The diseased disc was curetted and a sample of the granulation tissue and of the pus sent for study. Sections of the curettings showed chronic granu-

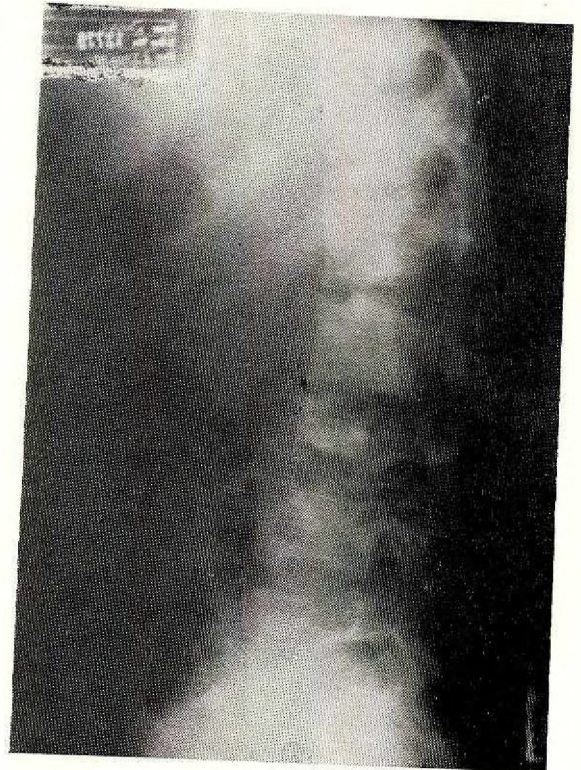


Fig. 1.—This shows the destructive changes present in the third and fourth lumbar vertebrae.

lation tissue with many giant cells, containing fungal spores which stained with P.A.S. and hexamine silver. This was reported as North American blastomycosis and spores and filaments of *Blastomyces dermatitidis* were grown on material from the spine after five weeks incubation at room temperature.

Treatment with Amphotericin B. was begun in May 1968 and 1½ grms. were given between then and July. The patient improved greatly but on discharge in July there was still a discharging sinus which later healed.

CASE V.

Dungwa Labini—aged 23 years originating from Malawi but living in the Mtoko district was admitted in May 1969 complaining of pain and swelling of the back of three months duration, beginning very shortly after his entry into Rhodesia. On examination he looked ill and was pale. There was no lymphadenopathy and the cardiovascular system was normal apart from a haemic systolic murmur. The examination of other systems was also normal apart from a left sided scoliosis and kyphosis in the lower thoracolumbar region with a paravertebral swelling in the area, which was more tender on the left than on the right side. A provisional diagnosis of tuberculosis of the spine with a paravertebral abscess was made and following correction of his anaemia 7.1 grms% and three weeks antituberculosis treatment, the abscess cavity was opened and a biopsy taken. Sections showed a mass of granulation tissue composed of histiocytes, lymphocytes, plasma cells and multinuclear giant cells containing fungal bodies which stained with P.A.S. and hexamine silver. Some of the bodies showed budding. The report was North American Blastomycosis.

Treatment was begun with Amphotericin B. but after approximately ten days treatment the patient developed cord compression. This was relieved by further operation, first a classical anterolateral extra pleural decompression on the right side and three months later as the patient had not improved, by transthoracic decompression. At this stage some granulation tissue was still present and the lesion possibly active. By January 1970 after 1½ grams of Amphotericin B. the patient's disease appeared to be arrested though he remained paraplegic, but with bladder control. No radiological or clinical abnormality was detected in this patient's chest.

CASE VI.

Dambuza Sofirma—a woman aged about 30 years from the Tribal Trust Land in the Karoi

district was admitted in April 1969 for discharging sores on the left side of her back which she had had for a year. This had begun as a lump the size of a fist on the left side of her back just below the rib margin, which later broke down. She had been given treatment for tuberculosis in a nearby clinic without success. On examination she was afebrile with a small goitre. Physical examination was otherwise completely normal except for the sinuses on the posterior chest wall which covered an area about 3¼ inches in diameter in which the skin was pigmented and fixed. In the centre was a granulomatous ulcer penetrating to the region of the lower rib. Fig. 2. Other investigations showed a haemoglobin of 7.4 grms% as the only significant finding. As the sequestra were removed from an infected rib and as after three weeks of antituberculosis therapy no improvement had occurred the area was explored. Extensive granulations and ramifying sinuses discharging granular yellow material were revealed and granulomatous lesions were scraped away from the 11th and 12th ribs. Histological examination of the material showed the now familiar picture of North American blastomycosis.

Although the patient was known to be pregnant it was decided to begin treatment with Amphotericin B. but four days later she aborted and had to have a curettage, the anaesthetic used being flurothane. Following this Amphotericin B. was recommenced, but a week later after a total of 475 mg. had been given the patient was noticed to be jaundiced, the serum bilirubin rising to 18.5 mg% of which 12.5 mg. was conjugated. The alkaline phosphatase only reached 18.5 King Armstrong units. Amphotericin was stopped but

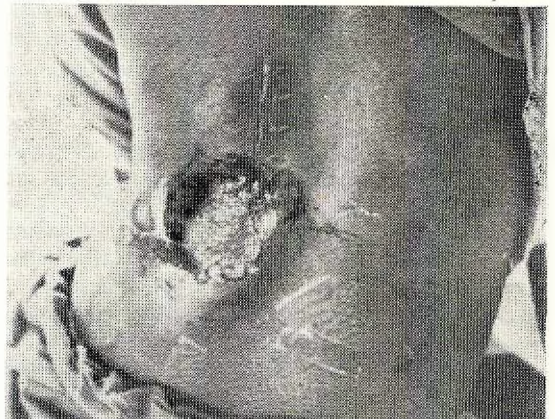

Fig. 2.—Note the large ulcerative lesion on the back.

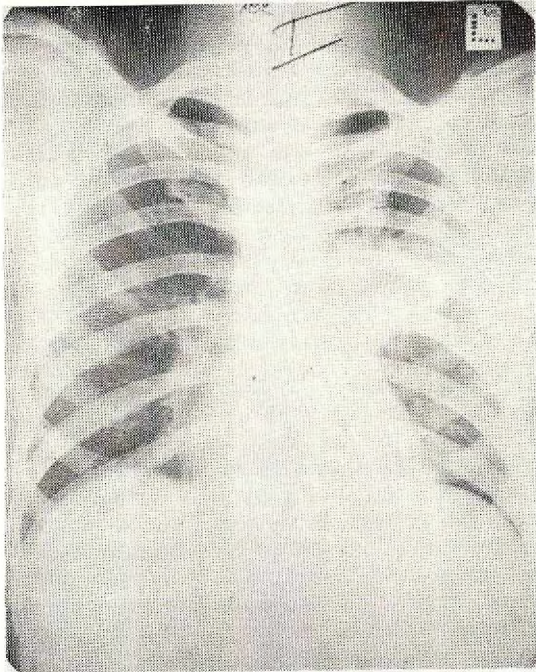


Fig. 3.—The lesion in the left lung extending from the hilum.

nevertheless the wound began to heal and it became very much smaller and without any further therapy the lesion on the back healed completely before the patient's discharge.

CASE VII.

Steri Makoni — a labourer aged about 40 years presented at Karoi Hospital with a three week history of pain at the back of the neck and a non-productive cough. Dr. Mostert, the Government Medical Officer, found that he was holding his neck stiffly. On examination he detected a few shotty lymph nodes in the occipital region. The chest was clear but an X-ray of the lungs revealed an opacity in the left mid-zone extending into the upper zone. A course of penicillin was given without benefit. The sputum showed no acid fast bacilli.

On 21st May, 1968, he was transferred to Harare Hospital. On admission his neck was obviously exceedingly painful and he still had discrete shotty cervical lymph nodes without induration. No skin lesions were detected. His chest was clinically clear and systemic examination was non-contributory. He was afebrile. The Heaf-test was positive.

The X-ray taken of his chest at Karoi showed an infiltrating lesion in the upper part of the left

chest extending from the hilar region and suggestive of an infective process or possibly a malignant process. (Fig. 3.) The chest radiograph taken after admission here showed little change from the initial plate and this made bronchogenic carcinoma seem a more likely diagnosis. A lateral X-ray showed in addition a clear area of rarefaction of some 12 or 13 mm. in diameter in the lower part of the sternum. The possibility that this was a metastasis from a bronchogenic carcinoma seemed very probable.

X-rays taken of the cervical spine showed a loss of the normal cervical curvature, a soft tissue swelling and a destructive lesion in the body of the fifth cervical vertebra involving particularly the lower and posterior borders but sparing the intervertebral discs. (Fig. 4.) Another picture taken a week later showed increased lung destruction but despite this the intervertebral discs were still reasonably well preserved.

The provisional diagnosis was bronchogenic carcinoma with bone secondaries but the general condition of the patient throughout his stay had been fairly good. The patient, who remained in hospital from 21.5.68 to 20.9.68 was afebrile except for very occasional rises of temperature

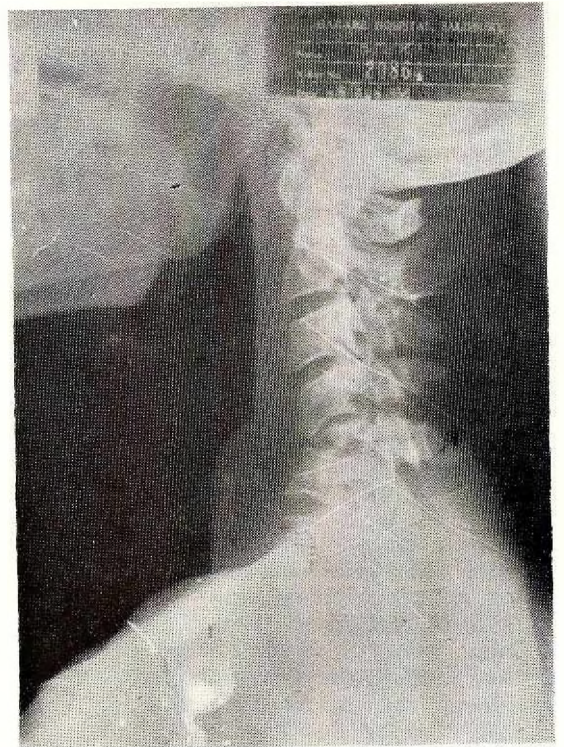

Fig. 4.—Gross destruction of C5.

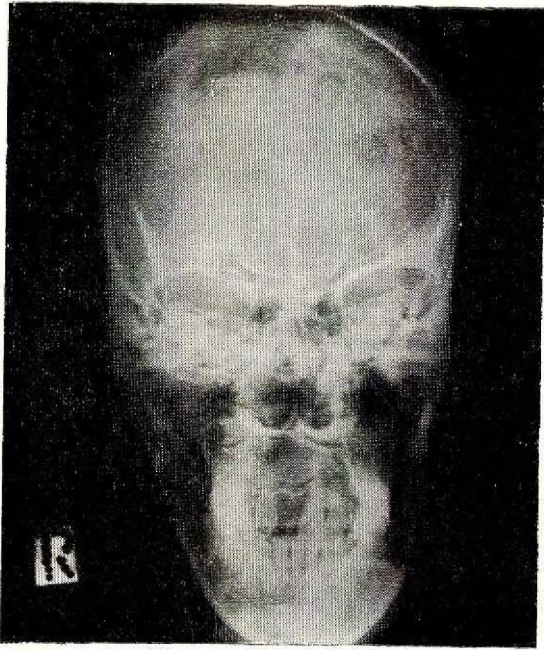


Fig. 5.—Notice the circular areas of destruction in the skull.

to 99° or 100° F. His E.S.R. was 84mm/one hour and haemoglobin 11.9G. Total leucocyte count 10 200.

We felt that further information about the nature of the soft tissue swelling in the retro-pharyngeal area was desirable and so Professor Mynors was asked to see the patient with a view to bronchoscopy. As he feared for the safety of the cervical spine he avoided this procedure. He did however excise one of the cervical lymph nodes but the histology was that a non-specific inflammatory condition. When he exposed the prevertebral muscles however, he found a soft tissue swelling and on opening, thick creamy pus that would have done well for tuberculous pus poured out. The vertebral body contained one or two small sequestra but the discs were completely normal. The sequestra were removed and the patient put in a plastic collar. The patient's discomfort was greatly relieved. The immobilisation of the neck made him virtually free from pain and his general condition seemed to improve.

Dr. W. M. Buchanan on section found spicules of bone around which were inflammatory cells most of which were neutrophils, histocytes and giant cells. The giant cells contained a number of vacuoles which on H & E section were characteristic of the spores of North American blastomycosis.

On the 4th July, 1968, the patient was put on Amphotericin B. He improved a great deal and continued to make steady progress once this treatment was started. The patient received a course of about 900 mg. of the drug in all and progress was most satisfactory.

He was discharged on 20.9.68, but further trace of him was lost. His neck pain was very much better. The abscess in the bone had presumably cleared and the lung lesion too had resolved. He was asked to return for a postspinal fusion in one month but he did not return.

CASE VIII

Nurara Daniel — aged 20 years, a prisoner, was admitted to hospital with a history of abscesses in his body. In December 1971 he was seen with multiple abscesses due to an underlying osteomyelitis of the skull (Fig. 5), right radius (Fig. 6) and right clavicle. Since that time he has had recurrent abscesses. After drainage he was discharged on 15th January, 1972. No organism was grown from the pus but it was noted that he had a positive V.D.R.L.

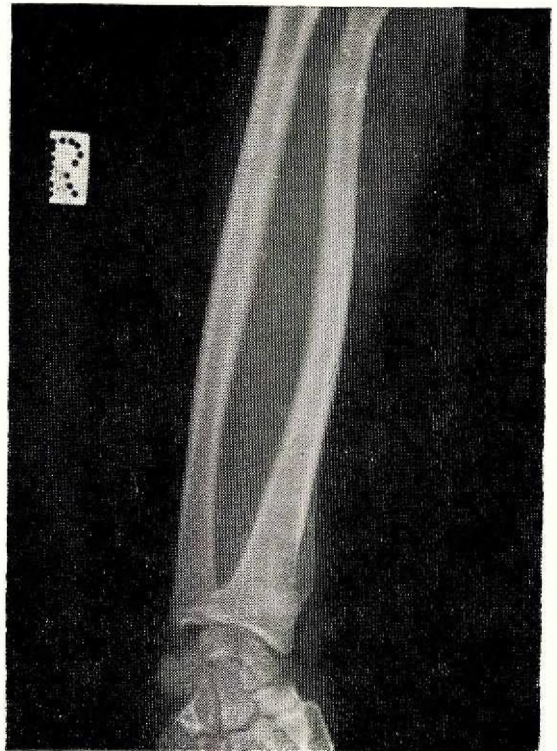

Fig. 6.—Periosteal reaction in the lower ends of the right radius and ulna.

The patient stated that he had been experiencing headaches for two months, and pain in the left side of his chest made worse by deep breathing. For one week he mentioned he noted that his sputum was tinged with blood. On X-ray a homogeneous dense shadow was present in his right upper zone. The other main findings were limited to the skull and extremities. The lesion in right forearm was tender and swollen. The left elbow joint was also swollen, warm and tender with limitation of movement. The right ankle joint was similarly swollen and a warm tender swelling was noted in the pretibial region over the left leg. The little finger of the right hand was swollen. A number of keloid scars were seen over the right and left arms and right shoulder. (Fig. 7.)

The patient was obviously ill. He was mildly pyrexial (99° to 100°F) and severely anaemic (5.4%). The E.S.R. was 105 mm. Pus from one of the abscesses was examined and numerous leucocytes and red cells were seen together with

yeast forms of *Blastomyces dermatitidis* in a moderate number of cells. Culture of the pus also grew this fungus. The patient was transfused and put on amphotericin B. (12.5 mg) daily in intravenous drip. The results were striking. The abscesses began to clear rapidly and the general condition of the patient improved out of all recognition.

SUMMARY OF THE FINDINGS

A number of features deserve mention:

1. Sex.

Out of the seven patients five were male and two were female. Our findings of more male as compared with female is in keeping with our findings of other workers. In the series Witorsch and Utz (1968) there were thirty-four male and six female. Although in our series all patients were African there would seem no reason for the European of Rhodesia not contracting the disease. Indeed, in the series of Witorsch and Utz, twenty-seven patients were Caucasian and thirteen Negro.

2. Age.

All the patients were under 50 years of age, the oldest being 48 years and the other six between 20 and 40 years.

Our findings on the disease so far show, as has been found in the U.S.A., that it is a disease affecting mostly the young and middle aged. (Witorsch and Utz, 1968.) Other workers in Africa have found much the same ages as in the present series. Emmons and Murray report a Ugandan patient of twelve years with the disease.

3. Fever.

In two of the patients there was no raised temperature, but in the other five the fever varied in severity. In only one case could the pyrexia be described as severe, 103°F and over, but in the rest it was either mild or moderate in degree.

4. Erythrocyte Sedimentation Rate.

This was greatly increased in all eight cases. In six it was over 100 mm. in one hour and in one it was 84 mm. According to Witorsch and Utz, the E.S.R. is raised in two-thirds of the patients and anaemia is fairly common as well. In our series anaemia, often severe, was notified. In four patients the haemoglobin was 50% (7.4g. per 100 ml.) or less and so a blood transfusion was given.

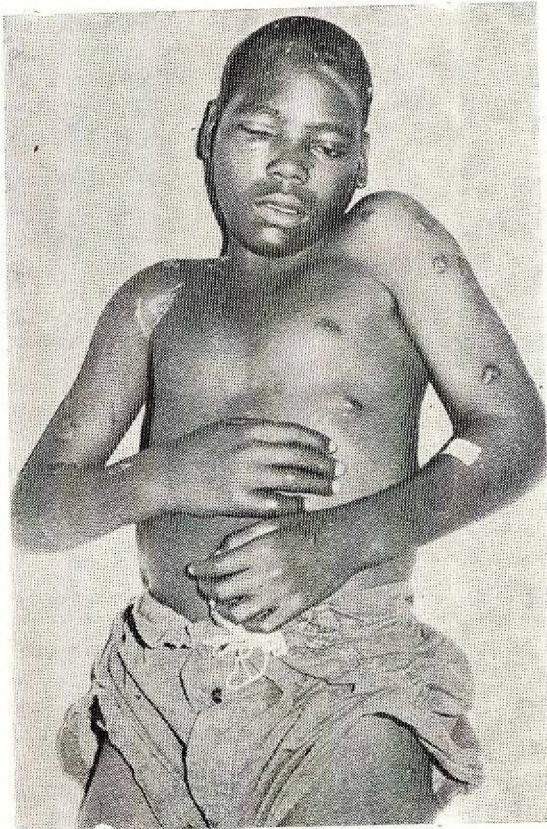


Fig. 7.—The healed keloid scars not uncommonly found in this disease.

5. *Bones.*

In every case there was evidence of bone involvement. In six of the eight patients the vertebrae were affected. (Two dorsal, two dorso-lumbar, one cervical and one lumbar.) Other bones attacked were the lateral malleolus, lower end of the tibia, ulna, radius, skull, wrist, scapula, ribs and carpus.

6. *Lungs.*

In five out of the eight patients the lungs were infected.

7. *Skin.*

In one of the patients there was a granulomatous skin lesion; in four discharging sinuses were present in the skin and in one a subcutaneous abscess (paravertebral) was noted. In one patient a retropharyngeal abscess was demonstrated and in one patient no abnormality was found in the skin.

Skin lesions are perhaps the most frequent finding. There are two types, verrucose and ulcerative. More suggestive of the disorder is the verrucose lesion and may resemble that due to the tubercle bacillus and epithelioma. Typically the lesion may exhibit central healing (Witorsch and Utz). Subcutaneous abscesses are noted in more than a third of the patients (Witorsch and Utz).

COMMENT

It is the rule for more than one system to be involved in the same patient in North American blastomycosis. About two-thirds of the cases of Witorsch and Utz showed involvement of two or more organ systems and most records report from one half to two-thirds of patients (Abernathy, 1959).

In most cases the skin and lungs are involved together in about a third of the cases (Witorsch and Utz, 1968). Slightly more than one-quarter of patients with Witorsch and Utz's series had an osteomyelitis. The bones most commonly affected include any of the vertebrae, pelvis, sacrum, skull, ribs and long bones. Arthritic involvement also occurs sometimes. Renal involvement has been reported but it would appear not to be from direct involvement of the kidneys. Urine cultures may be positive (Blackard and Berman, 1962).

In one of our series (Case V) no renal function was found on the right side but this may have been caused by bilharzial obstructive uropathy which is commonly encountered in this country. The gastro-intestinal tract and pleurae are two

sites in the body which appear to be resistant to the fungus and seldom are they involved in the disease.

Place of origin.

In six of the patients the disease appears to have been contracted in the north eastern part of Rhodesia. All the patients were farm labourers or working in close contact with the soil. We thought originally that all the patients were contracting the disease in one localised area of Rhodesia but now know of cases from almost every part of the country.

There can be no doubt that we are dealing with a fungal infection very similar or closely related to *Blastomyces dermatididis*. The clinical and pathological features of the disease conform with those seen in North American blastomycosis; the main effects are in the skin, lungs and bones. Ross and Goldring (1966) identified the fungus in cultures in two cases and it was also cultured in two of the present series.

Symmers (1968) who has visited many African territories is not convinced entirely that the disease now being called North American Blastomycosis is the same as that found in North America. Although the two diseases may be similar culturally, the tissue reaction to the fungus and the appearance of the fungi themselves in the tissues are distinct in the two groups of cases. He may be correct, but clinically there is no doubt that we are dealing with a fungal infection bearing strong similarities to that due to *B. dermatididis*. Furthermore, the response to Amphotericin B. is almost specific in our experience and this favourable response to treatment entitles us to label these cases as fungal and conforming to that of North American blastomycosis.

The disease process appears to be very responsive to Amphotericin B. The swelling regresses and at the same time the pus clears and any skin lesion or ulcer heals steadily. Whether with our one course of treatment the patient is cured or not we cannot say since the patient leaves the hospital once the disease appears to be arrested. But so far, none has returned with a relapse. A point worthy of note is that the disease appears to respond to doses of 900 mg. as a total course of treatment, less than we anticipated.

SUMMARY

The presence of a mycotic disease in Rhodesia conforming to the type described as North American blastomycosis is confirmed. The clinical features of eight cases are given.

The bones were almost always involved as well as the lungs. The skin however, may be affected either by granuloma developing in it or secondarily, by a sinus forming from an underlying bone abscess.

The disease is liable to be mistaken for pulmonary tuberculosis, secondary deposits in bone and granulomatous skin disease.

REFERENCES

1. ABERNATHY, R. S. (1959). *Ann. int. Med.*, **51**, 707.
2. BLACKARD, G. E. and BERMAN, H. I. (1962). *J. Urol.*, **88**, 94.
3. DROUHET, E., ENJALBERT, L., PLANQUES, J., BOLLINELLI, R. and MOREAU, J. (1968). *Bull. Soc. Path. Exot.*, **61**, 202. (Quoted from MAGALHAES, M. CAMPOS., DROUHET, E. and DESTOMBES, P. (1968). *Bull. de la Societe de Pathologie Exotique.* **61**, 210.
4. EMMONS, C. W., MURRAY, I. G., LURIE, H. I., KING, M. H., TULLOCH, J. A. and CONNOR, O. H. (1964). *Sabouraudia*, **3**, 306.
5. CATTI, F., DE BROE, M. and AJELLO, L. (1968). *Amer. J. trop. Med. and Hyg.*, **17**, 96.
6. GATTI, F., RENOIRTE, R. and VANDEPITTE, J. (1964). *Ann. Soc. Belge. Med. Trop.*, **44**, 1057.
7. MAGALHAES, M. J. CAMPOS: (1967), *Revista Portuguesa da Doenca de Hansen.*, **6**, 1.
8. ROSS, M. D. and GOLDRING, F. (1966). *C. Afr. J. Med.*, **12**, 207.
9. ROSS, M. D. (1967). *C. Afr. J. Med.*, **13**, 46.
10. SYMMERS, W. ST. C. (1968). *Systemic Mycoses*. Edited by Woltenholme, G. W. E. and Porter, R., Churchill, London.
11. VERMEIL, C., GORDEEFF, A. and HADDAD, N. (1954). *Ann. Inst. Pasteur*, **55**, 636. Quoted by MAGALHAES M. CAMPOS, DROUHET, E. and DESTOMBES, P. (1968). *Bull. de la Societe de Pathologie exotique.*, **62**, 210.
12. WITORSCH, P. and UTZ, J. P. (1968). *Medicine*, **47**, 169.

ACKNOWLEDGMENT

We wish to record the help received from Prof. John Mynors and Mr. Alan Roper, F.R.C.S. and thanks to Dr. Mark Webster, the Secretary for Health for the facilities of Harare Hospital.